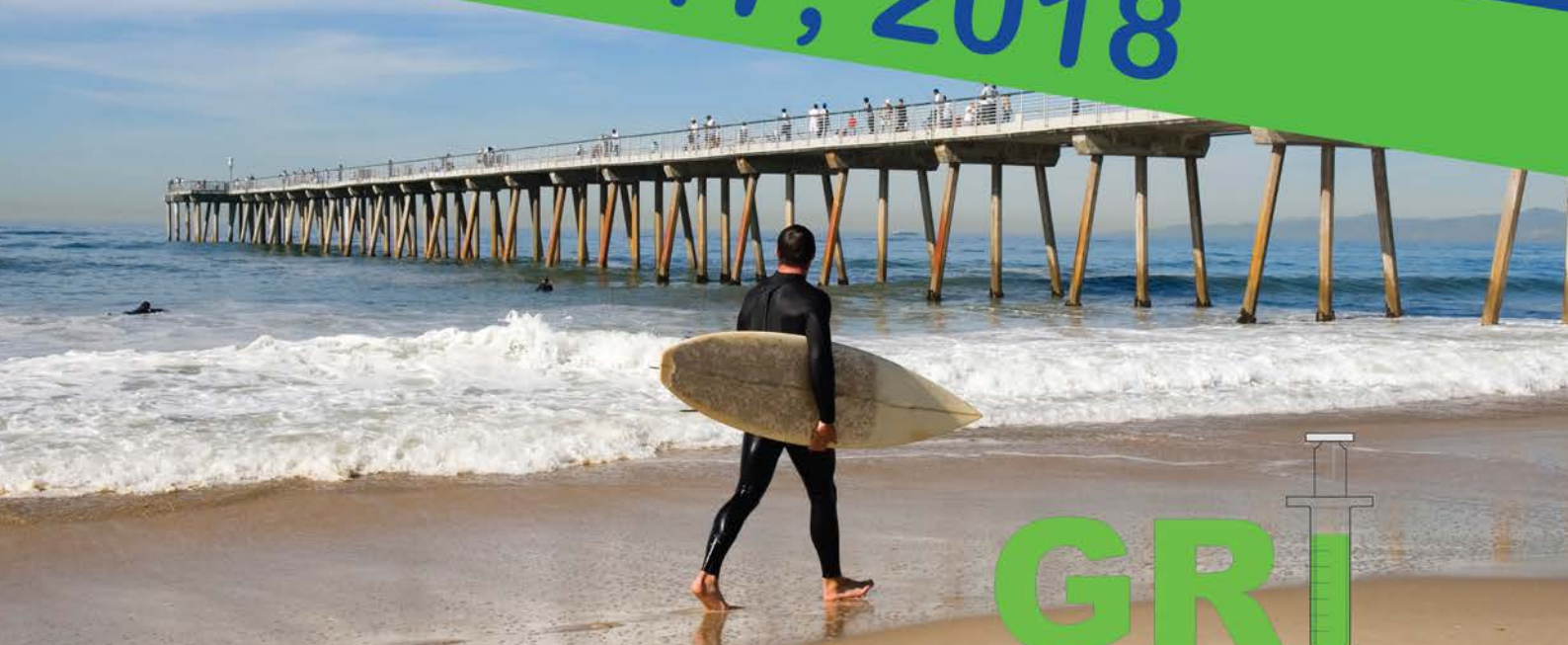



Los Angeles JW Marriott Los Angeles L.A.
March 17, 2018



GRI
BOI³



info@griboi2018.com
griboi2018.com
www.griboi.org

WELCOME

**GRIBOI Meeting, an Interdisciplinary Research Conference on
Image guided spine therapy, Biomaterials and Interventional implants**

GRIBOI 2018 will be held in conjunction with the start of the 2018 SIR Annual Scientific Meeting which will be held March 17-23.

It is part of our mission to mentor and develop residents, fellows, and SIR members in skills in medical device development. The **GRIBOI** is an international society dedicated to research and education in the field of bone and biomaterials, particularly focused on Spine intervention in benign and malignant disease.

For every topic and session, we will blend the current and future practice with the best current research. North American and International experts will interactively discuss and debate:

- New techniques in spine imaging
- Novel vertebral interventions in benign disease and the current status of trials
- Use of vertebral interventions to relieve pain in malignant disease
- Regenerative medicine and how to integrate Stem Cells and the use of PRP into practice
- Disc interventions and where does Ozone stand
- Spine practice building
- European advancements that the US does not have and the latest research in biomaterials from around the world
- Current status of 3D printing
- Role of biopsy in benign malignant and infected tissue
- And much more...

On behalf of the **GRIBOI** organization, volunteers and staff, I wish you an extraordinary, memorable and productive stay here in LA, California.

Sincerely,

Kieran Murphy MD, FRCPC, FSIR
2018 GRIBOI Meeting President
Professor of Radiology
Interventional Neuroradiologist
Toronto Western Hospital
University Health Network, Toronto

When: Saturday, March 17, 2018

Meeting location:

JW Marriott Los Angeles L.A. LIVE
900 West Olympic Boulevard
Los Angeles, California 90015 USA
Platinum Ballroom Sections F-J

Contact:

info@griboi2018.com



PROGRAM

SESSION 1: BUILDING A SPINE INTERVENTION PRACTICE

8.00 am - 10.00 am

Moderator: **K. Murphy**

1. Overview of Spine imaging for the Interventional radiologist.
K. Murphy
2. Overview of Vertebral interventions in benign disease.
A. Kelekis
3. Overview of vertebral interventions in malignant disease.
D.K. Filippiadis
4. Overview of vertebral implants and those available in the rest of the world.
B. Georgy
5. Bone cement Volume and its relationship to pain relief.
D. Beal
6. How do you run a spine practice and how do you bill with CPT hand out.
D. Beal

10.00 am - 10.20 am Coffee Break

PROGRAM

SESSION 2: NEW BIOMATERIAL DEVELOPMENT AND TECHNOLOGY

10.20 am – 12.20 pm

Moderators: **J-M. Bouler, A. Kelekis**

7. Sacral fractures and perfecting the technique.
R. Smith
8. Implants and Rebar in the pelvis.
S. Tutton
9. New insights into cell / biomaterial based disc therapies and imaging techniques.
S. Becker
10. Bone cements for osteoporotic vertebral fracture.
M. Bohner
11. Percutaneous fixation of the spine in spinal instability: what's new.
D. Beal
12. Radiofrequency ablation of Spine tumors, past present and future.
B. Georgy

12.20 pm – 1.00 pm Lunch Break

Volumetric versus areal cancellous bone mineral density in vertebrae: a preliminary comparison between computer tomography and radiography risk factors in vertebral osteoporotic fracture

Chentian Li¹, Yongqiang Jin¹, Wing Yuk Ip¹, William W. Lu¹

¹ Department of Orthopedics & Traumatology, The University of Hong Kong, Hong Kong, China

INTRODUCTION: The Bone Mineral Density is a well-known osteoporosis biomarker. However, instead of the total bone mineral density which presented both the cortical and cancellous bone together, the independent importance of cancellous bone mineral density in radiograph is less investigated. Here we compared the difference between areal and volumetric cancellous bone mineral density for vertebral osteoporotic fracture classification and discussed the merit of both radiography and computer tomography in osteoporotic fracture assessment.

METHODS: CT image datasets from 15 lumbar vertebral fractured and 15 non-fracture patients were collected from hospital. The CT images were obtained from Siemens SOMATOM Definition AS CT scanner with 120kV voltage and 300mAs current. The bone mineral density values were corrected using bone mineral density phantom. The cancellous bone region in the vertebrae at adjacent level of fractured vertebra were segmented as volume of interest using Mimics. A simulated anterior-posterior X-ray graph was transformed from the original segmented volume of interest CT image using MATLAB. The areal and volumetric average and standard deviation value of BMD in each sample were measured. The curve fitting and multivariable Logistic regression were performed in SPSS. The odds ratio of each factors was analysed, and the statistical significance was defined as $P < 0.05$.

RESULTS: The average volumetric BMD (vBMD) is 43.99314.40 mg/cm³, the standard deviation of volumetric BMD (vBMD std) is 15.4732.83 mg/cm³ in patients without fracture, and vBMD is 32.84310.82 mg/cm³, vBMD std is 14.0033.44 mg/cm³ in patients with fracture. The average areal BMD (aBMD) is 45.95314.90 mg/cm², the standard deviation of areal BMD (aBMD std) is 9.2633.58 mg/cm² in patients without fracture, and aBMD is 34.87311.79 mg/cm², aBMD std is 9.3935.23 mg/cm² in patients with fracture. The linear and exponential regression of aBMD and vBMD showed in fig1. The multivariable Logistic regression results for different models showed in Table 1.

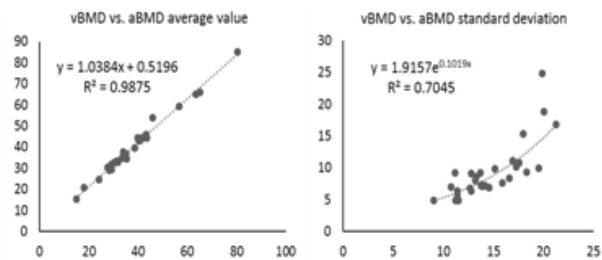


Fig. 1: Relationship between vBMD and aBMD (linear regression for average BMD, exponential regression for BMD standard deviation)

Table 1. Multivariable Logistic Regression for fracture status assessment in different models

Regression Model	Risk factors	Odds-Ratio	P	95% C.I.for EXP(B)
Single factor	vBMD	0.918	0.049	(0.84,0.99)
	vBMD std	0.855	0.208	(0.67,1.09)
	aBMD	0.929	0.055	(0.86,1.00)
	aBMD std	0.939	0.936	(0.85,1.19)
Combined	vBMD	0.922	0.084	(0.84,1.01)
	vBMD std	0.968	0.823	(0.73,1.29)
Combined	aBMD	0.897	0.039	(0.81,0.99)
	aBMD std	1.179	0.178	(0.93,1.50)
Age adjusted	vBMD	0.921	0.114	(0.83,1.02)
	vBMD std	0.972	0.859	(0.71,1.33)
Age adjusted	aBMD	0.885	0.029	(0.79,0.99)
	aBMD std	1.217	0.149	(0.93,1.59)

DISCUSSION & CONCLUSIONS: The regression models in this study indicated that the average volumetric BMD is a significant independent risk factor for vertebral fracture, while it is better to adjust the average areal BMD by the BMD standard deviation and age to achieve significant odds ratio. It is suggested that BMD in CT is significant enough when independently considered, while it is better to adjust BMD in radiography with other risk factors for vertebral fracture assessment. However, large sample studies should be performed for validation.

ACKNOWLEDGEMENTS: The work described on this abstract was partially supported by a grant from the Research Grants Council of the Hong Kong Special Administrative Region, China (Ref No. T13-402/17-N).

**New calcium phosphate bioactive glasses:
effect of the ortho-/pyro-phosphate ratio and
drying conditions**L Mayen¹, C Combes¹, O Marsan¹, C Rey¹, D Laurencin², J Soulié¹¹CIRIMAT, Université de Toulouse, INP - ENSIACET, Toulouse, France.²Institut Charles Gerhardt de Montpellier, Université de Montpellier, Montpellier, France

INTRODUCTION: Silicate-based bioactive glasses have been developed as biomaterials for bone and soft tissue substitution [1-2]. Despite promising properties [3-4], phosphate-based glasses have been poorly studied especially when synthesized in mild conditions [5]. Very recently a new family of calcium ortho-/pyro- phosphate glasses has been prepared by soft chemistry using salt precursors, water as solvent and low temperature [6]. The objective of the present study is to evaluate the effect of three synthesis parameters, the initial ortho-/pyro- ratio in solution and the gel washing and drying steps on the obtained material.

METHODS: The material is prepared using calcium and pyro/orthophosphate salts separated solutions (CaCl_2 and $\text{Na}_4\text{P}_2\text{O}_7/\text{Na}_3\text{PO}_4$). The calcium solution is added to the phosphate solution. The mixture is then centrifuged and a gel is obtained after several washings. Finally, the gel is dried. The effect of the ortho-/pyro- ratio (in the 0-8 range), the number of washings (0 to 2) and the drying temperature (ambient temperature (20°C to 140°C)) has been investigated. The as-prepared materials have been characterized by SEM, XRD, ^{31}P solid-state NMR, and Raman and FTIR spectroscopy.

RESULTS: We showed that depending on the initial ortho-/pyrophosphate ratio in solution, the material can be crystalline (with initial ortho-/pyro = 0), amorphous for the lowest ratios (> 0) or partially crystalline for the highest ratios. A thorough study using cryo-Raman and ^{31}P solid state NMR has led to qualitative and quantitative data on the structure and composition of the different materials prepared. It was demonstrated that the evolution of a transient amorphous phase toward a crystalline phase could be avoided by the washing step. The amorphous structure could be explained by the degrees of freedom of pyrophosphate entities and the inhibitory effect of orthophosphate ions on calcium pyrophosphate phase crystallization. Depending on the washing, drying temperature and moulding we can obtain a hydrogel, particles/granules or a monolith of glasses (Fig. 1).




Fig. 1: Macroscopic views of ortho/pyrophosphate glasses as monolith (a), granules (b) and SEM micrograph of a granule (c).

DISCUSSION & CONCLUSIONS: This study demonstrated that the ortho-/pyrophosphate ratio in solution and the gel washing and drying steps are three crucial parameters that can lead to amorphous, crystalline or mixed materials. Even if further investigations will be necessary to fully understand the formation process and structure of these materials, this new family of bioactive glasses leads to promising and versatile materials to be used as monolith, granules or injectable hydrogel for bone filling and regeneration.

REFERENCES: 1 J.R Jones, (2013) Acta Biomaterialia 9:4457-86. 2V. Miguez-Pacheco, L. L. Hench, A. R. Boccaccini (2015) Acta Biomaterialia 13:1-15. 3 T. Kasuga (2005) Acta Biomaterialia 1:55-64. 4 D.S. Brauer, R.M. Wilson, T. Kasuga (2012) Journal of Non-Crystalline Solids 358:1720-23. 5E.A. Abou Neel, D.M. Pickup, S.P. Valappil, et al. (2009) Journal of Materials Chemistry 19:690-701. 6J. Soulié, P. Gras, O. Marsan, et al. (2016) Acta Biomaterialia 41: 320-7.

ACKNOWLEDGEMENTS: The authors thank the Agence Nationale de la Recherche (PyVerres project n°ANR-16-CE19-0013) for supporting this research work.

Abstract_3

European Cells and Materials Vol. NN. Suppl. N, 20xx (page htu)

ISSN 1473-2262

Clinical experience in 50 patients implanted with a prophylactic implantable medical device indicated in severe osteoporosis or impending pathologic fracture in proximal femur.

F Deschamps¹, O Pellerin², JD Laredo³, C Mastier⁴, G Leleup⁵, P Reynders⁶, F Cornelis⁷

¹Gustave Roussy Cancer Campus, Villejuif, France; ²APHP HEGP, Paris, France; ³APHP Lariboisière, Paris, France; ⁴Centre Léon Bérard, Lyon, France; ⁵CHU Rouen, Rouen, France; ⁶CHU Brugmann, Brussels, Belgium; ⁷APHP Tenon Hospital, Paris, France

INTRODUCTION: An innovative implant, Y-STRUT® (Hyprevention, France) was designed to provide prophylactic reinforcement of the proximal femur in patients suffering from a first hip fracture due to osteoporosis or presenting osteolytic metastases. We present our clinical experience^{2,3,4} on the first 50 patients implanted between February 2013 and December 2017.

METHODS: Prophylactic consolidations were performed under the same anaesthesia of a hip fracture surgical treatment in the opposite side for osteoporotic patients at high risk of contralateral fracture. For oncologic patients at high risk of hip fracture (Mirels' score ≥ 8), procedures were planned during multidisciplinary meetings.

A first prospective pilot study, HIP#0, was completed with the first 10 osteoporotic patients, with a follow-up of 5 years that is still ongoing. Another prospective pilot study, HIPPON, was completed with the first 10 oncologic patients implanted with a 1-year follow-up. Then an observational post-market study HIPPON100 was initiated to include the following 100 patients in the same indication with a 2-year follow-up. From March 2016, 30 patients were included in this study that is still ongoing.

Mid-term safety and tolerance of the studied device are assessed with several criteria, such as walking recovery, pain, radiographic control and adverse events. Clinical efficacy is evaluated through the occurrence of fractures during post-operative follow-up.

RESULTS: Ten elderly patients (mean 8237yo) had contralateral prophylactic consolidation because of a severe osteoporosis (mean T-score -3.6430.8) resulting in first hip fractures. Median follow-up ranges from 4 to 46 months.

Ten patients (mean 6236yo) were treated because of impending pathological fractures (mean Mirels' score 9.4) related to femoral neck osteolytic metastases. Median follow-up was 8 months (1-14). The follow-up is still ongoing for the next 30 oncologic patients.

In all patients, wound healing was achieved, with no case of wound infection, bleeding, or inflammation. Radiographic exams performed at 3-month-follow-up revealed that the device was well integrated in the bone. For the osteoporotic cohort, no hospitalisation lengthening was needed. All patients recovered walking and no pain was reported at 3 weeks. No fracture occurred up to now. For oncologic patients, a very short hospitalisation duration was reported, suggesting that day-surgery case is possible. Mean pain decreased from 3.632.9 at baseline to 1.330.8 at 1 year. Chemotherapy may not be stopped before device implantation and radiotherapy could be done after.

DISCUSSION & CONCLUSIONS: Results from these studies demonstrated the tolerance and safety as well as the short-term clinical efficacy of the studied device in both indications when performed following the operating instructions. Additional data need to be recorded on a greater number of subjects with longer follow-up to confirm the clinical benefits of Y-STRUT® implantation.

REFERENCES: 1M. Szpalski et al (2015) A new approach to prevent contralateral hip fracture: Evaluation of the effectiveness of a fracture preventing implant. Clin Biomech 30(7):713-9. 2M. Szpalski et al (2017) Contralateral Prophylactic Reinforcement in Case of First Low-Energy Hip Fracture: First-in-Man Clinical Data of a New Percutaneous Internal Fixation Device. J Osteopor Phys Act 5:202. 3FH Cornelis et al (2017) A novel implant for the Prophylactic Treatment of Impending Pathological Fractures of the Proximal Femur: Results from a prospective, First-in-man study. Cardiovasc Intervent Radiol 40:1070-1076. 4FH Cornelis et al (2017) Percutaneous internal fixation with Y-STRUT® device to prevent both osteoporotic and pathological hip fractures: a prospective pilot study. J Orthop Surg Res 9;12(1):27.

ACKNOWLEDGEMENTS: This template was modified with kind permission from eCM Journal.

PROGRAM

ABSTRACT AND SCIENTIFIC SESSION

1.00 pm – 3.00 pm

Moderators:

M. Bohner, G. Baroud

Abstract_4

European Cells and Materials Vol. NN. Suppl. N, 20xx (page htu)

ISSN 1473-2262

Comparative biomechanical study of a new transpedicular vertebral device and vertebroplasty for the treatment or prevention of vertebral compression fractures

M.Aebi¹, C.Maas², T.Di Pauli Von Treuheim³, H.Friedrich³, F.Cornelis⁴, H-J.Wilke³

¹Salem Spital Orthopedic Department, Bern, Switzerland. ²Hyprevention, Clinical Search, Pessac, France.

³Institute of Orthopaedic Research and Biomechanics, Trauma Research Center Ulm (ZTF), University Hospital Ulm, German. ⁴APHP Tenon Hospital, Paris, France

INTRODUCTION: Worldwide, there are approximately 1.4 million new vertebral compression fractures (VCFs) reported each year and osteoporotic VCFs affect nearly 25% of individuals over 50 years old [1]. It is estimated that only one third of vertebral fractures result in medical attention [2]. However, non-surgical management may lead to a double risk for future fractures (22%) compared to vertebral augmentation procedures (11%) [3]. The main current therapeutic option available on the market is vertebroplasty, considered as the gold standard for VCFs surgical treatment. A comparative study was performed between a novel transpedicular implant (V-STRUT®, Hyprevention, France) and vertebroplasty. This study aims to assess the biomechanical efficacy of this implant in resurrecting and fortifying the osteoporotic vertebra following a vertebral body fracture.

METHODS: A total of 17 vertebrae from 3 human osteoporotic spine segments (T9-L5) were selected and isolated. Vertebral compression fractures were generated by eccentric compressive loading on the vertebral body until a vertebral height reduction of 25%. Then the vertebrae were either filled with PMMA bone cement alone according to vertebroplasty technique (control group; n=8) or implanted with V-STRUT® implant combined with bone cement (device group; n=9). Following the treatment, a new compressive loading was performed in the same conditions and maximal load and stiffness, as well as total energy to fracture were measured. These data were used to compare both treatment groups and analyse their efficacy in supporting axially applied load on the vertebral body.

RESULTS: Fracture force and energy to fracture

were both increased either after V-STRUT® implantation or vertebroplasty compared to when the initial fracture was generated. Mean increase percentage between the initial value and the post-treatment value for each parameter were +77% vs +39% regarding fracture load and +126% vs +99% for energy to fracture, for the device group vs vertebroplasty group respectively.

No pedicle fractures were observed in both groups, and no implant breaking or bending was observed in the device group.

DISCUSSION & CONCLUSIONS: These results show the ability of V-STRUT® combined with bone cement to reinforce the vertebral body strength, with an at least equivalent biomechanical performance as vertebroplasty. Although not significant, a trend for higher efficacy of the device compared to vertebroplasty was observed. Therefore, further clinical investigation needs to be undertaken in order to confirm these results and demonstrate any clinical superiority of V-STRUT® thanks to its pedicle anchorage over vertebroplasty.

REFERENCES: 1 M. A. Hazzard et al (2014) Asian Spine J. 5:605-14 "Compression Fractures and Impact on US Healthcare Resource Utilization,". 2 R. V. Chandra, A. J. Yoo, and J. A. Hirsch (2013) Pain Physician J., vol. 16, no. 4, pp. 309-320 "Vertebral Augmentation: update on safety, Efficacy, cost effectiveness and increased survival? ". 3 I. D. Papanastassiou, A. Filis, M. A. Gerochristou, and F. D. Vrionis, (2014) Biomed Res. Int., vol. 2014, no. 2 "Controversial issues in kyphoplasty and vertebroplasty in osteoporotic vertebral fractures".

ACKNOWLEDGEMENTS: This template was modified with kind permission from eCM Journal.

Abstract_5

Hydration mechanism of a calcium phosphate cement modified with phytic acid

K Hurle¹, U Gbureck², T Brueckner², M Brueckner², J Neubauer¹, F Goetz-Neunhoeffler¹

¹GeoZentrum Nordbayern, Mineralogy, Friedrich-Alexander-University of Erlangen-Nuernberg, Erlangen, Germany. ²Department for Functional Materials in Medicine and Dentistry, University of Wuerzburg, Germany

INTRODUCTION: Calcium phosphate cements are applied for bone repair due to their excellent biocompatibility [1]. A good injectability of the cement paste is of particular importance to allow application through tiny cannulas.

Phytic acid (IP6), a natural component present in plants like rice or corn [2], was expected to improve cement injectability by altering the zeta potential of the cement particles. IP6 is further known to retard brushite precipitation [3]. Hence the suitability of IP6 as an additive to improve injectability and adjust the setting time was investigated in this study.

METHODS: Cement pastes were fabricated by adding an aqueous mixing liquid containing H₃PO₄ and IP6 to β -tricalcium phosphate (β -TCP, Ca₃(PO₄)₂) powder. The molar ratio of H₃PO₄: β -TCP was 1:1, IP6 concentrations of 5, 10, 15 and 20 wt.% related to the β -TCP content were chosen. A sample with 0.5 M citric acid monohydrate was used as reference. The water to cement ratio (w/c) was 0.5.

Injectability of the cement pastes was examined by inserting a syringe with a 2 mm diameter cannula into a Z010 static universal testing machine (Zwick). The percentage of paste injected and the force necessary for injection were determined.

Hydration of the IP6 containing cement samples was investigated by isothermal calorimetry at a TAM Air isothermal calorimeter (TA instruments) at 37 °C. Mixing of the pastes was performed by internal stirring for 1 min. Samples containing 10 and 20 wt.% IP6 were additionally investigated by quantitative in-situ X-ray diffraction combined with the G-factor method, an external standard method which allows determination of absolute phase quantities [4].

RESULTS: While the injectability of the reference system was rather poor (3.3 ± 3.1 %), it was strongly increased by IP6 addition (95.7 ± 0.4 % for IP6_5, about 98 % for all other concentrations). A force of 18.3 ± 7 N was applied for IP6_5, while only about 4 N were necessary for IP6 concentrations ranging from 10 to 20 wt.%.

The calorimetry curves of the different samples

demonstrated a clear retarding effect of IP6 on the cement reaction (Fig. 1).

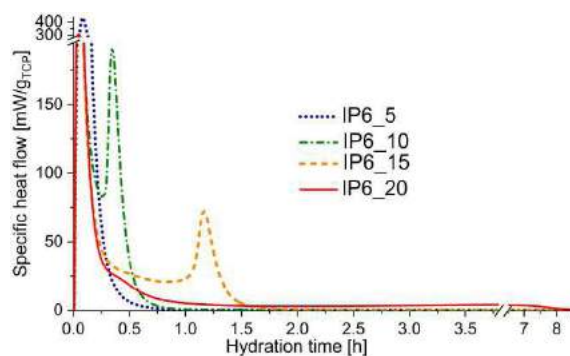


Fig. 1: Calorimetry curves of β -TCP mixed with H₃PO₄ solution and IP6 at T = 37 °C; w/c = 0.5.

Rapid initial formation of monocalcium phosphate monohydrate (MCPM, Ca(H₂PO₄)₂·H₂O) from H₃PO₄ and parts of the β -TCP was followed by simultaneous dissolution of the remaining β -TCP and MCPM, accompanied by monetite formation. Monetite was the only crystalline hydration product detected by XRD, its formation was strongly retarded by increasing IP6 concentration.

DISCUSSION & CONCLUSIONS: In the IP6 modified cement systems H₃PO₄ and β -TCP reacted to monetite (CaHPO₄) via formation of MCPM as intermediate hydration product. As IP6 delayed the reaction, it is a useful retarder to adjust the setting reaction to acceptable setting times.

The substance was further proven a versatile additive for achieving injectable cement pastes due to its formidable increase of injectability.

REFERENCES: 1 S. Larsson, G. Hannink (2011) Injury 42(SUPPL.2):S30-S34. 2 E. Graf, J.W. Eaton (1990) Free Radical Bio Med 8:61-69. 3 F. Grases, M. Ramis, and A. Costa-Bauzá (2000) Urol Res 28:136-140. 4 D. Jansen, Ch. Stabler, F. Goetz-Neunhoeffler et al. (2011) Powder Diffr 26:31-38.

ACKNOWLEDGEMENTS: The research was funded by the Deutsche Forschungsgemeinschaft (DFG, German Research Foundation) - grants HU 2498/1-1 and GB 1/22-1.

Abstract_6

Bone metastases treatment by a local delivery of gallium

Strazic-Geljic I¹, Schmid-Antomarchi H¹, Schmid-Alliana A¹, Bouler JM², Scimeca JC¹, Verron E²
¹iBV Université Côte d'Azur, CNRS, INSERM, France. ²CEISAM, Université Nantes, UMR CNRS 6230, Nantes, France

INTRODUCTION: Bone tissue is one of the most favoured sites for breast tumours metastases, and bone lesions are preferentially localized in spine and pelvic bone. Patients diagnosed with advanced breast cancer mostly develop bone metastases characterized by severe osteolytic lesions (1). Subsequently, bone metastases lead to severe bone pain, bone instability, fractures, spinal cord compression, hypercalcemia and bone marrow aplasia.

Our previous data demonstrated that gallium (Ga) was an inhibitor of bone resorption (2,3). Furthermore, using a calcium phosphate (CaP)-based bone substitute loaded with Ga (CaP-Ga), we evidenced that Ga decreased osteoclastic differentiation, up-regulated the expression of osteoblastic marker genes involved in bone matrix maturation, and enhanced *in vivo* bone substitute reconstructive properties (4). The aim of this study was to explore CaP-Ga potential in the context of bone reconstruction following the resection of a bone tumour.

METHODS: Using an established *in vitro* model associating conditioned medium from breast cancer cells (MDA-MB-231 and MDA-231BO) with osteoclast precursor cells, we explored Ga activity on osteoclastogenesis

in an aggressive bone metastatic environment
RESULTS: We first observed that Ga dose-dependently inhibited osteoclastogenesis induced by tumour cells medium. To mimic a more aggressive environment where pro-tumorigenic factors are released from bone matrix, metastatic breast tumour cells were stimulated with TGF- β , a major cytokine involved in bone metastases development. In these circumstances, Ga still inhibited cancer cells medium-driven osteoclastogenesis (Fig 1). Lastly, we evidenced that Ga directly and strongly impacted cancer cells proliferation/viability, as well as the expression of major osteolytic factors.

DISCUSSION & CONCLUSIONS: This is the first time that antitumor properties of Ga have been specifically studied in the context of bone metastases. Our data strongly suggest that, through its action against the vicious cycle involving bone cells and tumour cells, Ga represents a relevant and promising candidate for a local delivery upon the resection of bone metastases from breast cancer.

REFERENCES: 1 Verron E et al. Drug Discov Today 2014; 19: 1419-26. 2 Verron E et al. Br J Pharmacol 2010; 159: 1681-92. 3 Verron E et al. Biochem Pharmacol 2012; 83: 671-9. 4 Strazic Geljic I et al. J Tissue Eng Regen Med 2017.

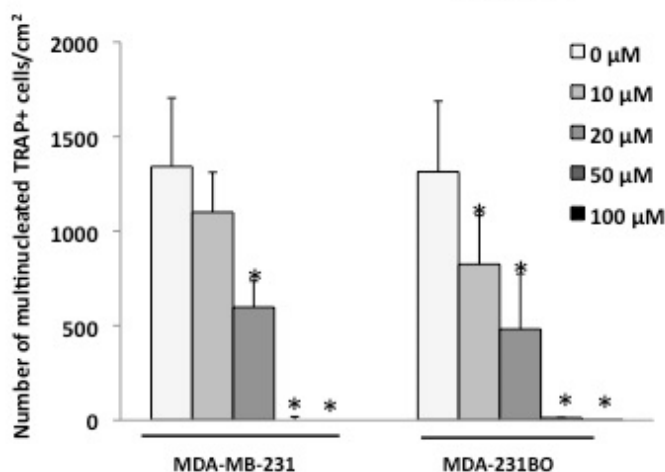


Figure 1: Dose-dependent effect of Ga on the formation of mature osteoclasts

PROGRAM

ABSTRACT AND SCIENTIFIC SESSION

1.00 pm – 3.00 pm

Moderators:

M. Bohner, G. Baroud

Abstract_7

Propionibacterium Acnes and Type 1 Modic Changes in the Cervical Spine: An Observational Study.

M. Georgy^{1,3}, F. Vaida¹, M. Stern³, K. Murphy²

¹University of California San Diego Division of Biostatistics and Bioinformatics, Department of Family Medicine and Public Health, 9500 Gilman Dr, La Jolla, CA 92093; ²Joint Department of Medical Imaging, University Health Network (UHN), 399 Bathurst Street, Toronto, Ontario, M5T 2S8; ³Southern California Institute of Neurological Surgery, 705 East Ohio Ave. Escondido, CA 92025.

Corresponding Author:

Mark Georgy, University of California San Diego Department of Family Medicine and Public Health Southern California Institute of Neurological Surgery, 705 East Ohio Ave. Escondido, CA 92025.

ABSTRACT

Purpose: Research on the association between Propionibacterium Acnes in the disc space and type 1 Modic changes (MC1) in adjacent vertebrae is limited and has produced mixed results. The prevalence of bacteria in intervertebral discs contradicts the prior understanding that the skeletal anatomy is sterile, yet opens new treatment possibilities. We investigated the relationship of P. acnes and MC1 in the cervical spine.

Methods and Materials: We attained IRB approval for intraoperative biopsies of patients undergoing routine cervical spine surgery for degenerative disc diseases. The disc material was cultured aerobically and anaerobically for 7 days. All pre-operative MR images were evaluated for Modic changes by a board-certified neuroradiologist. Medical records were reviewed for other spine interventions prior to surgery.

Results: Over a 36-month period, we collected cultures from 48 patients. Of these, 14 patients tested positive for P. acnes (29%) at one or more levels. Additionally, 13 patients had MC1 (27%) at one or more levels. 54% (95% CI: 27%-84%) of patients who had MC1 were also positive for P. acnes, while 20% (95% CI: 7%-33%) of patients who had MC1 were not. The difference between these proportions was 34% (95% CI: 4%-64%). Fisher's Exact Test produced a p-value of 0.03 for P. acnes crossed with MC1, and a p-value of 0.53 for P. acnes crossed with prior procedures.

Conclusion: We conclude that P. acnes was prevalent in the degenerated cervical discs, and that MC1 predicted a higher risk for P. acnes. We also found that the prevalence of P. acnes was not associated with previous intervention (p = 0.53). If these results are validated by future studies, they could have a major impact on the standard of care for neck pain.

PROGRAM

ABSTRACT AND SCIENTIFIC SESSION

1.00 pm – 3.00 pm

Moderators:

M. Bohner, G. Baroud

Abstract_8

Retention of gadolinium-based contrast agents: A key role of bone tissue?

Egli R. J.¹, Böhm I.¹, Cullmann J. L.¹, Heverhagen J. T.¹

¹University Institute of Diagnostic, Interventional and Paediatric Radiology, Inselspital, University of Bern, Bern, Switzerland

Recent reports demonstrate retention of Gd after contrast enhanced MRI in tissues, especially in the brain. Even though an impact on the patients' health has not yet been proven these findings provoked US and European agencies to release safety recommendations concerning the use of gadolinium based contrast agents. Current efforts are focused on identifying potential effects of Gd retention in the brain. Even though of undisputable importance, it neglects the fact that within bone tissue up to 1000 times higher concentrations of Gd can be found. Bone is considered the storage compartment whereof Gd is released through bone turnover exposing the body for years. Therefore, targeting the interaction of Gd with bone tissue may be the pivotal pathway to reduce Gd retention in the brain. To that end a profound knowledge of the interaction of Gd with bone tissue is essential. This presentation reviews the literature addressing the entire sequence from Gd administration, deposition in bone tissue, effect on bone cells, release from bone tissue to systemic redistribution. It will become clear that we are far from understanding these events, even though the community is aware since many years that Gd is

retained in bone tissue. Experimental approaches will be discussed how the many gaps may be filled to understand the role of bone tissue in the retention of Gd after contrast enhanced MRI.

Imaging findings or procedure details: This educational poster reviews the. We are currently initiating an interdisciplinary project and we will present our systematic approach to fill in the many gaps. This project will encompass the entire sequence of Gd administration, deposition in bone tissue, effect on bone cells, release from bone tissue, and systemic redistribution using in vitro, ex vivo and in vivo approaches.

Conclusions: Bone tissue may be a long-term storage compartment for Gd after contrast enhanced MRI. Therefore, targeting the interaction of Gd with bone tissue may be the pivotal pathway to reduce Gd retention in the brain. To that end increasing the knowledge of the interaction of Gd with bone tissue is essential.

Learning objectives: To understand the role of bone tissue in the retention of gadolinium (Gd) in brain tissues after contrast enhanced MRI.

Abstract_9

AGN1 local osteo-enhancement procedure (LOEP): an emerging, minimally-invasive surgical treatment utilizing a triphasic calcium based implant material to address osteoporosis-related bone loss in the proximal femur

SM Heining¹, R Pfeifer¹, MJ Vehling¹, HC Pape¹

¹Department of Trauma, Zurich University Hospital, Zurich, CH

INTRODUCTION: Millions of people with osteoporosis are at risk of fracture due to the disease's underlying pathology – bone loss. Pharmaceuticals reduce hip fracture risk, but require compliance and time before being effective. Surgical approaches aimed at strengthening bone and preventing fractures using non-resorbable materials have been studied with limited success¹. AGN1 LOEP (local osteo-enhancement procedure) is an emerging surgical treatment that rapidly, substantially, and durably increases bone strength. The procedure was developed to be safe, repeatable, and minimally-invasive. This abstract presents this emerging approach that delivers a proprietary, triphasic, calcium-based implant material (AGN1) into the proximal femur to locally address bone loss in osteoporotic proximal femurs.

METHODS: AGN1 LOEP is performed with the patient sedated and positioned on a standard fracture table. Once the patient is positioned and the lateral femur is prepped and draped, a site for skin incision is marked just distal to the greater

trochanter. Following the injection of local anesthesia, a 1 cm skin incision is made and the iliotibial band is incised. A 2.5mm guide pin is advanced to the area of the sub-capital femoral epiphysis at a center/center position in the femoral neck as confirmed by fluoroscopy. A 5.3mm cannulated drill is placed over the guide pin and advanced through the lateral cortex to the end of the guide pin. The drill and guide pin are removed and a working trough is inserted through the lateral cortical portal. A specially-designed probe debrider is used to loosen fat and nonstructural elements in the proximal femur. Those elements are then removed by irrigation and suction. AGN1 is manually injected under low pressure into the enhancement site in the proximal femur using a 30 degree curved injection cannula and fluoroscopy as control. The working trough is removed and the incision site is closed. The triphasic implant material is a self-setting and hardens within 20 minutes after injection. The AGN1 LOEP procedure is illustrated in the Figure below demonstrating the successful injection of the implant material into the proximal femur.

RESULTS: The proprietary AGN1 implant material has demonstrated ability to form new bone in osteoporotic proximal femurs².

DISCUSSION & CONCLUSIONS: More than 30 orthopedic surgeons have been successfully trained to perform AGN1 LOEP. There is large potential for a safe², repeatable, and minimally-invasive procedure, with initial results demonstrating rapid and durable increases in proximal femur strength in patients with osteoporosis^{2,3}. AGN1 LOEP offers an emerging approach to address osteoporotic bone loss in the proximal femur.

REFERENCES:

1. BoneKey Reports 5, Article number: 854 (2016)
2. Howe et al., Osteoporos Int (2017) 28(Suppl 1): S75 <https://doi.org/10.1007/s00198-017-3945-z>
3. Keaveny et al., J Bone Miner Res, 32:S11, 2017; data on file AgNovos Healthcare

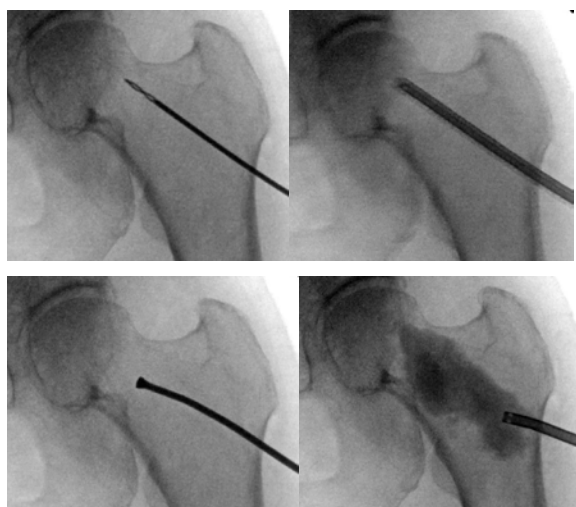


FIGURE: Upper Left: Guide pin; Upper Right: cannulated drill; Lower left: Debrider; Lower Right: AGN1 injection.



SESSION 3: DISC INTERVENTION

3.00 pm – 3.50 pm

Moderators: **K. Murphy, S. Becker**

13. Disc space interventions

A. Kelekis

14. Role of stem cells in disc disease

D. Beal

3.50 pm – 4.20 pm Coffee Break

SESSION 4: ONCOLOGY, AND ABLATION

4.20 pm – 5.50 pm

Moderators: **A. Brook, B. Georgy**

15. MRgFUS and other ablations and their effect on bone strength.

S. Tutton

16. New percutaneous strategies and devices for cementoplasty and fixation on spine and hip.

F. Cornelis

17. Combined treatments for pain palliation: current evidence and further developments

F. Cornelis

18. The role of Cryoablation in Bone.

P. Munk

19. The Rebar concept.

A. Kelekis

5.50 pm GRIBOI GENERAL ASSEMBLY **A. Kelekis**

sponsors

Medtronic

Further, Together



IZI Medical Products

From concept to care.

MEDMIX[®]

hyprevention[®]